

Phyto-pharmacological activity of *Tecoma capensis* (thumb.) Lindl. plant flowers

D Suneeta¹, Y.R.K.V. Tirupathi Rao²

¹ Assistant Professor of Botany, Government Degree College, Thorrur, Mahabubabad, T.S

² Assistant Professor, Department of Botany & Microbiology, Acharya Nagarjuna, University, Guntur, Andhra Pradesh, India

Abstract

The liver and kidney disorders have been world major population problem. Despite its frequent occurrence, high morbidity and high mortality, its medical management is currently inadequate, no therapy has been successfully prevented the progression of nephritis and hepatic diseases. Plant drugs have been known to play vital role in the management of liver and kidney diseases. The plant *Tecoma capensis* belongs to family Bignoniaceae. The other species of this plant have reported for the hepatoprotective activity but no activities were reported on the flowers of *Tecoma capensis*. The present study is performed to reveal that the hepatoprotective and nephroprotective activities of *Tecoma capensis* in rifampicin induced hepatotoxic and nephrotoxic in rats, to prove its claims in folklore practice against liver and kidney disorders.

Keywords: Rifampicin, *Tecoma capensis*, hepatotoxic, nephrotoxic and flower

Introduction

The largest organ in the human body is liver. Liver have been plays a very important role in the metabolism of foreign compounds entering the body. The exposure to the foreign compounds may be through consumption of alien/contaminated foods, from exposure to chemical substances in the occupation environment or through synthetic drugs consumed for various pathological conditions. These compounds have many toxic manifestations on the human liver [1]. The liver gets injured also by viruses, chemicals, alcohol and autoimmune diseases. Liver diseases remained one of the serious health problems, and medicinal plants and herbs have been in use for treating these in the Indian traditional systems of medicine, especially Ayurveda. The present modern age demands proof on a scientific basis to justify the various medicinal uses of herbs [2]

After decades of serious obsession with the modern medicinal system, people have started looking at the ancient healing systems like Ayurveda a, Siddha and Unani. This is because of the adverse effects associated with synthetic drugs [3]. *Tecomaria capensis* (Bignoniaceae) is also known as Cape-honey suckles [4] is a climber common to the tropical zone. It is grown as an ornamental plant in gardens. Traditionally the leaves were used to treat pneumonia, enteritis, diarrhea and tonic. It was reported to contain analgesic, antimicrobial, anti-fungal and antipyretic, antioxidant activity [5]. Many researchers have screened for analgesic, anti-inflammatory, anti-pyretic, hepatoprotective, anti-ulcer, anti-oxidant, anti-microbial and anti-nociceptive activities on this plant on various parts. The other species of this plant have reported for the hepatoprotective activity but no activities were reported on the flowers of *Tecoma capensis*. The present study was performed to assess the hepatoprotective and nephroprotective activities of *Tecoma capensis* in rifampicin induced hepatotoxicity and nephrotoxicity in rat model, to prove its claims in folklore practice against liver and kidney disorders.

Materials and Method

Collection and preparation of extracts

The plant material was collected from the plant *Tecomaria Capensis*, which are collected during the month of June at Dept. of botony, Kakatiya University, Warangal (Dist.) of Telangna. Then it was authenticated by Dr. P. Satyanarayana Raju, professor, Department of Botany, Kakatiya Universit. The flower part of *Tecomaria capensis* was dried at room temperature and grounded into powder and passed through 60# sieve. The powder (500gm) has been extracted successively in soxhlet extraction with methanol. The extraction sediments were filtered and the filtrate was dried at 40°C in an oven to get dried product. The extract was fractionated using methanol, ethanol and ethyl acetate. Plant extraction fractions obtained were prepared different concentrations and used for hepatoprotective and nephroprotective activities in-vitro and in-vivo modal.

Chemicals and instruments

All chemicals used in the study were pure. Reference standard Rifampicin obtained from Symed Pharm. Pvt. Ltd, Hyderabad.

Preliminary phytochemical screening

The extract was subjected to preliminary phytochemical screening was performed by using standard protocol. 5-7

The methanolic extract of the plant flowers part of *Tecomaria Capensis*, carried out test tube qualitative reactions were gave positive results for alkaoloids, flavonoids, glycosides, saponins and tannins, phenols, steroids and tri-terpinoids. And also carried out TLC study for the methanolic extract.

Acute toxicity studies

Although medicinal plants may produce several biological activities in humans, but generally very little is known about their toxicity. Though, safety should be the overriding criterion in the selection of medicinal plants for use in healthcare systems, several drugs produce acute and obvious

signs of toxicity which are used in the traditional medicine. The present study was undertaken to investigate acute toxicity of methanolic extract prepared from flowers of *Tecomaria Capensis*.

Animal Model

The methanolic extract of *Tecomaria Capensis* was pharmacologically screened for its toxic and biological effects in selected animal models. All animal studies were performed as per the guidelines of CPCSEA and Institutional Animal Ethical Committee (IAEC). CPCSEA Reg. No: 1516/PO/a/11/CPCSEA dated 01-011- 2011. Albino mice of either sex weighing between 16 - 25 g procured from Sainath Agencies, Hyderabad - 48, for experimental purpose. Then the animals were acclimatized for 7 days under standard husbandry conditions.

Experimental design

A total of 36 animals were divided into 6 groups (6 no's in each group). Group 1 is served as normal control received only vehicle for 28 days (distilled water, p.o) whereas groups 2,3,4,5 and 6 received 20% ethanol (3.76 g / kg / day) to induce hepatotoxicity for *][poiuy76t54320.

water and administered orally) respectively. After oral administration, the blood samples were withdrawn by retro-orbital puncture at 8th, 15th, 22nd and 29th days respectively. The collected blood samples were centrifuged at 2500 rpm for 15 min to get clear serum and were used to analyse the biochemical parameters such as serum glutamic pyruvic transaminase (SGPT), serum glutamic oxaloacetic transaminase (SGOT), alanine amino transaminase (ALP), bilirubin, and total protein. Finally, on the 29th day the animals were sacrificed using high dose of ether and the livers of all experimental animals were isolated.

Histopathological Evaluation

The liver and kidney organs were fixed in neutral buffered formalin for 24 h. Sections of tissue from liver and kidney organs were examined histopathologically to study the hepatoprotective and nephroprotective activity of *Tecomaria capensis*. The liver and kidney organs were fixed in 10% buffered formalin and were processed using a tissue processor. The processed tissues were embedded in paraffin blocks and about 5-µm.

Result

Acute toxicity studies were carried out on *Tecomaria capensis* up to the dose of 2000 mg/kg which demonstrated that the extract did not show any sign of toxicity and mortality. However, there was a decrease in physical activity, which was observed only at the dose of 2000 mg/kg. Thus, the present doses regime (100 and 200 mg/kg) was chosen for further studies. The results of hepatoprotective and nephroprotective activities of crude methanolic extracts of this plant at a dose of 100 mg/kg, 200mg/kg and 400mg/kg on rats intoxicated with standard silymarin (25 mg/kg) were illustrated in the table 1, fig-1 and 2. The tables also showed the comparison of effects among the untreated (control) and Rifampicin treated (negative control) group with the drug treated group of rats. Treatment with methanolic *Tecomaria capensis* at different dose levels (100, 200 and 400 mg/kg) and standard silymarin (25 mg/kg) significantly decreased the enzymes serum glutamic pyruvic transaminase (SGPT), serum glutamic oxaloacetic transaminase (SGOT), alanine amino transaminase (ALP) and bilirubin levels as compared to disease control group. Oral administration of methanolic *Tecomaria capensis* at different dose levels (100, 200 and 400 mg/kg) and standard silymarin (25 mg/kg) significantly increases the enzymatic antioxidants like superoxide dismutase, catalase, glutathione levels and reduces the lipid peroxidise levels when compared to the disease control group. All the above parameters indicating the hepatoprotective activity of METC against rifampicin-induced liver cell damage.

Methanolic extract of *Tecomaria capensis*, 400 mg/kg body weight was produced a significant reduction in the elevated serum biochemical parameter (Bilirubin, SGPT, SGOT and ALP) levels and elevated the decreased enzymatic antioxidant (SOD, catalase, glutathione) levels in Rifampicin induced hepatotoxic rats. These effects were found to be comparable and even more than that of the standard Silymarin (25 mg/kg). Oral administration of Rifampicin significantly decreased the body weight and increased the serum biochemical parameters such as blood urea nitrogen, serum creatinine and serum uric acid. Methanolic *Tecomaria capensis* at different dose levels (100, 200 and 400 mg/kg) significantly increased the body weights and lowers the serum bilirubin biochemical parameters in Table-1.

Table 1: Effect of METC on Bilirubin and % Reduction in Bilirubin Levels in Hepatotoxic Rats

Time in days (↓)	Effect of The Flowers of <i>Tecoma Capensis</i> on Bilirubin Levels in Hepatotoxic Rats						% Reduction in Bilirubin Due to the Treatment with METC In Hepatotoxic Rats					
	Control	Rifampicin	Silymarin	Methanolic Extract of Flowers of <i>T. CAPENSIS</i>			Control	Rifampicin	Silymarin	Methanolic Extract of Flowers of <i>T. CAPENSIS</i>		
Dose (mg/kg) →	-	1000	25	100	200	400	-	1000	25	100	200	400
0	0.516±0.047	1.817±0.030***	1.517±0.030***	1.683±0.030***	1.517±0.030***	1.500±0.025***	-	-	-	-	-	-
8	0.600±0.068	2.217±0.030***	1.350±0.022***	1.433±0.033***	1.383±0.016***	1.267±0.021***	8.58±14.52	17.22±1.294***	10.88±1.285***	14.57±3.013***	7.60±1.977***	15.47±1.248***
15	0.566±0.066	2.600±0.036***	1.167±0.021***	1.267±0.021***	1.267±0.021***	0.950±0.022***	6.80±14.81	34.42±3.643***	22.83±2.446***	24.52±2.386***	15.40±2.089***	36.63±1.245***
22	0.516±0.047	2.900±0.036***	0.950±0.042***	1.083±0.040***	1.133±0.033***	0.766±0.021***	0.78±11.46	37.27±1.342***	37.32±2.640***	35.57±2.322***	25.22±1.907***	48.77±1.587***
29	0.583±0.047	3.250±0.042***	0.566±0.033***	0.866±0.021***	0.700±0.044***	0.500±0.036***	9.75±10.22	44.03±0.939***	62.55±2.229***	48.43±1.309***	53.22±3.087***	66.67±2.305***

n=6 significant at p<0.05*, 0.01**, 0.001***

Table 2: result isuric acid produced Rifampicin by nephrotoxicity was analysis for the nephroprotective effect produced by methanol extract of *Tecomaria capensis* is 400

mg/kg body weight was found to be same as that of the standard Silymarin (25 mg/kg).

Table 2: Effect of METC on Serum URIC Acid and % Reduction in Serum Uric Acid Levels in Toxic Rats

Time in days (↓)	Effect of the Flowers of <i>Tecoma Capensis</i> on Serum Uric Acid Levels in Nephrotoxic Rats						% Reduction in Serum Uric Acid Due to the Treatment with Metc in Nephrotoxic Rats					
	Control	Rifampicin	Silymarin	Methanolic Extract of Flowers of <i>T. CAPENSIS</i>			Control	Rifampicin	Silymarin	Methanolic Extract of Flowers of <i>T. CAPENSIS</i>		
Groups →												
Dose(mg/kg) →	-	1000	25	100	200	400	-	1000	25	100	200	400
0	5.633±0.194	10.38±0.047***	9.783±0.030***	10.0±0.036***	9.73±0.033***	9.617±0.047***	-	-	-	-	-	-
8	5.567±0.316	10.82±0.030***	9.350±0.042***	9.73±0.033***	9.46±0.021***	9.10±0.051***	1.45±7.912	4.0±0.559***	4.38±0.508***	2.63±0.483***	2.66±0.333***	5.33±0.311***
15	5.300±0.178	11.42±0.030***	8.967±0.033***	9.23±0.33***	9.00±0.068***	8.58±0.079***	5.80±4.590	9.28±0.583***	8.43±0.212***	7.63±0.542***	7.50±0.506***	10.70±0.390***
22	5.817±0.299	12.28±0.047***	7.650±0.042***	8.75±0.061***	8.48±0.047***	7.23±0.091***	2.63±6.76	15.43±0.391***	21.77±0.332***	12.47±0.730***	12.80±0.256***	24.73±1.010***
29	5.150±0.172	13.28±0.060***	5.833±0.120***	7.83±0.076***	6.85±0.076***	6.01±0.119***	7.90±1.796	21.53±0.491***	40.32±1.219***	21.63±0.780***	29.55±0.815***	35.65±0.996***

Table 3: result is serum creatinine levels produced by Rifampicin produced nephrotoxicity was analysis for the nephroprotective effect produced by methanol extract of

Tecomaria capensis is 400 mg/kg body weight was found to be same as that of the standard Silymarin (25 mg/kg).

Table 3: Effect of Metc on Serum Creatinine and % Reduction in Serum Creatinine Levels in Toxic Rats

Time in days (↓)	Effect of the Flowers of <i>Tecoma Capensis</i> on Serum Creatinine Levels in Nephrotoxic Rats						% Reduction in serum Creatinine Due to the Treatment with METC in Nephrotoxic Rats					
	Control	Rifampicin	Silymarin	Methanolic Extract of Flowers of <i>T. Capensis</i>			Control	Rifampicin	Silymarin	Methanolic Extract of Flowers of <i>T. Capensis</i>		
Groups →												
Dose(mg/kg) →	-	1000	25	100	200	400	-	1000	25	100	200	400
0	1.083±0.079	3.0±0.035***	2.883±0.030***	2.967±0.021***	2.833±0.021***	2.70±0.025***	-	-	-	-	-	-
8	1.050±0.076	3.50±0.036***	2.483±0.030***	2.767±0.021***	2.058±0.030***	2.417±0.030***	3.88±8.635	14.2±1.354***	13.78±1.175***	6.66±0.852***	8.78±0.801***	10.45±1.114***
15	1.067±0.080	4.0±0.036***	1.950±0.042***	2.267±0.021***	2.0±0.025***	1.883±0.030***	1.75±8.00	24.93±0.978***	32.32±1.381***	23.53±0.785***	29.35±1.055***	30.20±1.060***
22	1.10±0.089	4.50±0.036***	1.045±0.022***	1.950±0.022***	1.750±0.022***	1.450±0.223***	1.28±11.25	33.27±0.954***	49.63±1.039***	34.2±0.883***	38.18±0.560***	46.23±0.988***

n=6 significant at p<0.05*, 0.01**, 0.001***

Fig 1: A. Group I (Normal control), B. Group II (Rifampicin) Section of liver with normal cell structure Section of liver showing centriolobular necrosis, C. Group III (Standard-Silymarin), D. Group IV (*Tecomaria capensis* -200), E. Group V (METC-400) Section of liver showing significantly reduced Necrotic area. The hepatoprotective effect produced by methanol extract of *Tecomaria capensis* is 400 mg/kg was found to be more than that of the standard Silymarin (25 mg/kg). Histological changes such as cortical glomerular, peritubular blood vessel congestion and interstitial inflammation were observed in disease control group. The Methanolic *Tecomaria capensis*, extract at 400 mg/kg had significantly prevented these histological changes.

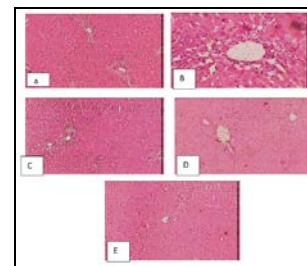


Fig 1: A. Group I (Normal control), B. Group II (Rifampicin) Section of liver with normal cell structure Section of liver showing centriolobular necrosis, C. Group III (Standard-Silymarin), D. Group IV (*Tecomaria capensis* -200), E. Group V (METC-400) Section of liver showing significantly reduced Necrotic area

Figure 2: A. Group I (Normal control, B. Group II Rifampicin induced Necrotic area, C. Group III (Standard-Silymarin), D. Group IV (*Tecomaria capensis* -200), E: Group V (METC-400) Section of liver showing significantly reduced Necrotic area. The nephroprotective effect produced by methanol extract of *Tecomaria capensis* is 400 mg/kg was found to be same as that of the standard Silymarin (25 mg/kg). Histological changes such as cortical glomerular, peritubular blood vessel congestion and interstitial inflammation were observed in disease control group. The Methanolic *Tecomaria capensis*, extract at 400 mg/kg had significantly prevented these histological changes.

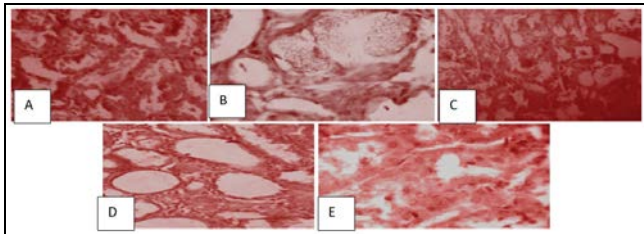


Fig 2: A. Group I (Normal control, B. Group II Rifampicin induced Necrotic area, C. Group III (Standard-Silymarin), D. Group IV (*Tecomaria capensis* -200), E: Group V (METC-400) Section of liver showing significantly reduced Necrotic area

Discussion

The plant *Tecoma capensis* belong to the family Bignoniaceae. The floral parts of the above plants are selected for the investigation of hepatoprotective and nephroprotective activity. The methanolic extract of the flowers of *Tecoma capensis* gave positive results for steroids, alkaloids, tannins, glycosides, saponins, flavanoids, carbohydrates and proteins. An LD₅₀ study of methanolic extract was conducted up to a dose of level of 2 mg/kg and no mortality was observed in any of the animals which induced the practically nontoxic nature and safety of the extract. There was a significant dose related decrease in serum biochemical parameters of liver like SGPT, SGOT, ALP and bilirubin at different dose levels (100, 200 and 400 mg/kg). Oral administration of methanolic extract of flowers of *Tecoma capensis* at different dose levels (100, 200 and 400 mg/kg) produced a significant dose dependent increase in the enzymatic antioxidants of liver like superoxide dismutase, catalase and glutathione levels. Administration of methanolic extract of flowers of *Tecoma capensis* at doses of 100, 200 and 400 mg/kg produced increase serum biochemical parameters of kidney like serum uric acid, serum creatinine and blood urea nitrogen levels.

From the Pharmacological screening, we can conclusively state that the methanolic extract of flowers of *Tecoma capensis* have hepatoprotective and nephroprotective activity and were comparable with that of standard silymarin. The hepatoprotective and nephroprotective activity produced by METC may be due to presence of steroids, triterpenes, alkaloids, glycosides, flavonoids, saponins, tannins and proteins.

Conclusion

In conclusion, this study provides evidences of methanolic extract for the hepatoprotective and nephroprotective activities of *Tecomaria Capensis* flowers, which could partly contribute to its ethno-medical use. However, further

investigation is required to isolate the active constituents responsible for this activity and to elucidate the exact mechanism of action.

References

1. Rajesh MG. Protective activity of *glabra* Linn on carbon tetrachloride-induced peroxidative damage. *Indian J Pharmacol*, 2004; 36:284-87.
2. Pohocha N, Grampurohit ND. Antispasmodic activity of the fruits of *Helicteres osora* Linn *Phytother Res*, 2001; 15:49-52.
3. Nardkarnis KM. *Indian material medica*, Popular prakashan pvt. ltd, 2002; 1:1080-1081.
4. Panduraju T, Rao PRS, Kumar VS. Antibacterial activity of tecoma capensis methanolic extract of leaves. *Asian Journal of Plant Science and Research*, 2011, 102-115.
5. Kathiresan Prabhu, Pradip Kumar Karar, Siva Hemalatha, Kathiresan Ponnudurai and Prakash Mankar, Anti-ulcer activity of tecoma capensis methanolic extract of leaves. *Der Pharmacia Sinica*. 2011; 2(2):131-141.
6. Madhavan V, Pravin Kumar, Zamabad P, Guru Deva MR, Yoganarsimhan SN, Antihelmenthetic activity of tecoma capensis methanolic extract of leaves. *Indian Journal of Traditional Knowledge*. 2009; 8(2):176-180.
7. Doss A. Preliminary phytochemical screening of some Indian medicinal plants. *Ancient science of life*, 2009; 29:12-16.
8. Evans WC. *Trease and Evans Pharmacognosy*, 15th edition, W.B. Saunders Company Ltd., London, 2005, 191-393.
9. Kokate CK, Purohit AP, Gokhale SB, *Pharmacognosy*, 39th Edition, Nirali Prakashan, Pune, 2005, 607-611.
10. Divya S, Rahul N, Tripta S, Rupesh K. Gautam. In vitro anti-inflammatory and antiarthritic activity of hydroalcoholic extract of *Pongamia pinnata* (L.) Pierre seed. *International Journal of Pharma Research & Review*. 2013; 2(12):20-25.
11. Madan S, Prashant S, Neeraj U, Yogesh S. In vitro antiarthritic activity of Manilkara zapota Linn. *Asian J Pharma Tech*. 2011; 1(4):123-124.