



Evaluation of antiasthmatic activity of *Lawsonia inermis* leaves

D Nalini Devi*, Sreenu Thalla, A Narendra Babu, J Naga Lakshmi, N Chandreshta

Department of Pharmacology, Chalapathi Institute of Pharmaceutical Sciences, Guntur, Andhra Pradesh, India

Abstract

Lawsonia inermis (Henna) is a cosmetic dye. Henna leaves were extensively used as dye for nails, hands, hair and textile and also used in treating certain skin infections, headache, jaundice, amebiasis and enlargement of the spleen. In the present study an attempt was made to evaluate the anti-asthmatic activity of ethanolic extract of *Lawsonia inermis* (EELI) leaves against ovalbumin (OVA) -induced asthma in albino mice. The parameters assessed were evaluation of lung inflammation, OVA-specific immunoglobulin E titre by ELISA and histopathology of lung. EELI at the dose range of 100 and 200 mg/kg i.p inhibited ovalbumin induced asthma by decreasing the release of inflammatory mediators. The present study indicates that *Lawsonia inermis* has significant anti-asthmatic property.

Keywords: *Lawsonia inermis*, Asthma, Inflammation, Ovalbumin Ig E, ELISA

Introduction

Asthma is a chronic inflammatory disease of the airways characterized by recurrent episodes of airflow obstruction and reversible respiratory difficulties. Asthma affects more than 300 million people worldwide and this number is estimated to increase to 400 million by 2025 because of urban development [1]. Airway inflammation plays a major role in the pathophysiology of asthma and mainly occurs through the Th-2 immune response. Inflammatory process perpetuation promotes substantial structural changes in the lung architecture that are caused by repeated lesions and repair [2]. Morphological changes associated with asthma in mouse lung tissue, including increased mucus secretion in the bronchioles, eosinophil infiltration around the bronchioles and vessels, and hyperplasia of goblet cells and epithelial cells [3]. The drugs currently used in modern medicine for the treatment of this disease are far from appropriate since they offer only symptomatic relief, produce numerous adverse effects and may lose potency on continued usage [4]. The typical symptoms of asthma range from cough to obstructive apnea, which may occur due to excessive mucus development, hyperplasia of goblet cells, epithelial cell shedding, thickening of the basement membrane, as well as infiltration of eosinophils and lymphocytes [5]. *Lawsonia inermis* (Family: Lythraceae) leaves are generally used as dye for nails, hands, hair and textile. The leaves of *Lawsonia inermis* is used widely for curing various diseases like skin problems, headache, jaundice, amebiasis and enlargement of the spleen [6]. The present study was designed to evaluate the anti-asthmatic effect of the ethanolic extract of the dried leaves of *Lawsonia inermis* (EELI) on ovalbumin induced Asthma in mice.

Materials and Methods

Procurement of Plant Material & Authentication

For the present investigation, fresh leaves of *Lawsonia inermis* were collected from medicinal plant garden of Chalapathi Institute of Pharmaceutical Sciences, Guntur.

The plant is identified and authenticated by Dr. M. Raghu Ram, Department of Botany and Microbiology, Acharya Nagarjuna University, Nagarjuna Nagar, Guntur.

Extraction

The dried leaves (300g) were powdered and passing through 80 mesh and then extracted with 95% ethanol using a soxhlet apparatus. The extract was filtered through cotton wool plug and dried in vacuum rotary evaporator at 40-60°C under vacuum and complete dryness.

Phytochemical Studies

Test for Steroids

- **Liebermann-Burchard test:** 4 gm of extract was treated with 0.5ml of acetic anhydride and 0.5ml of acetic acid. Then concentrated H₂SO₄ was added slowly and blue green color was observed for terpenoids and reddish-brown color for steroids.
- **Salkowski test:** 5 gm of extract was mixed in 2 ml of chloroform, and concentrated H₂SO₄ (3ml) was carefully added to form a layer. A reddish blue colouration in the chloroform layer and green fluorescence in acid layer was formed to show positive results for the presence of terpenoids.

Test for Flavonoids

- **Shinoda Test:** Pieces of magnesium ribbon and HCl concentrated were mixed with aqueous crude plant extract after few minutes and pink color shows the presence of flavonoids.
- **Alkaline Reagent Test:** 2 ml of 2.0% NaOH mixture was mixed with extract; concentrated yellow color was produced, which became colorless when we added 2 drops of diluted acid to mixture. This shows the presence of flavonoids.
- **H₂SO₄ test:** A fraction of the extract was treated with Conc.H₂SO₄ and observed for the formation of orange color.

Test for Tannins

- **Ferric chloride test:** 0.5g of the dried powdered sample was boiled in 20ml of water in a test tube and then filtered. A few drops of 0.1% FeCl₃ was added and observed for brownish green-black or a blue-black coloration.
- **Lead acetate test:** 2ml of plant extract was combined with 2ml of distilled water. 0.01g lead acetate was added to this combined solution and shaken well. Development of white turbidity and precipitate indicates the presence of tannins.
- 10 ml of bromine water was added to the 0.5 g aqueous extract. Decoloration of bromine water shows the presence of tannins.

Test for Saponins

- **Foam test:** About 2g of the plant extract was mixed with 10ml of distilled water and shaken vigorously for a stable persistent froth. Appearance of froth indicates the presence of saponins. About 2 g of the powdered sample was boiled in 20 ml of distilled water in a water bath and filtered. 10ml of the filtrate was mixed with 5 ml of distilled water and shaken vigorously for a stable persistent froth. The frothing was mixed with 3 drops of olive oil and shaken vigorously, then observed for the formation of emulsion.

Test for Alkaloids

- **Mayer's Test:** Filtrates were treated with Mayer's reagent (Potassium Mercuric Iodide). Formation of a yellow-colored precipitate indicates the presence of alkaloids.
- **Wagner's Test:** Filtrates were treated with Wagner's reagent (Iodine in Potassium Iodide). Formation of brown/reddish precipitate indicates the presence of alkaloids.
- **Dragendorff's Test:** Filtrates were treated with Wagner's reagent (Potassium bismuth iodide). Formation of orange brown precipitate indicates the presence of alkaloids.
- **Hager's Test:** Filtrates were treated with Wagner's reagent (Potassium mercuric iodide). Formation of Yellow precipitate indicates the presence of alkaloids.

Test for Phenols

- **Ferric chloride test:** About 2 gm plant extract was taken in water and warmed at 45-50°C. Then 2 ml of 0.3% FeCl₃ was added. Formation of green or blue color indicates the presence of phenols.

Test for Polysaccharides

- **Molisch's test:** The extract was treated with 2-3 drops of 1% alcoholic naphthol and 2 ml of concentrated sulphuric acid was added along the sides of the test. Violet colour was formed which indicates the presence of carbohydrates.
- **Fehling's test:** The extract was treated with 1 ml of Fehling's solution and heated in a boiling water bath. A reddish orange precipitate was obtained.
- **Benedict's test:** To 0.5 ml of the extract, 0.5 ml of Benedict's reagent was added. The mixture was heated on boiling water bath for 2 min. A characteristic red colored precipitate indicates the presence of sugar.

Test for Proteins

- **Millon's reagent:** To the extract, Million's reagent (mercury in nitric acid) was added. Formation of white precipitate which turned red on heating indicates the presence of proteins.
- **Ninhydrin reagent:** The extracts are heated with 5% Ninhydrin (in butanol) solution in boiling water bath for 10 min and development of purple or bluish color indicated the presence of amino acids.
- **Biuret test:** To the extracts, 4% sodium hydroxide and 1% copper sulphate solution are added and formation of violet or pink color indicates the presence of proteins.

Test for Glycosides

- **Liebermann's Test:** 2 ml of acetic acid and 2 ml of chloroform were added to the plant extract. The mixture was then cooled and then H₂SO₄ concentrated was added. Green color shows the entity of aglycone, steroidal part of glycosides.
- **Keller-Kiliani Test:** A solution of glacial acetic acid (4.0 ml) with 1 drop of 2.0% FeCl₃ mixture was mixed with the 10ml aqueous plant extract and 1ml H₂SO₄ concentrated. A brown ring formed between the layers which showed the entity of cardiac steroidal glycosides.
- **Salkowski's Test:** 2 ml of conc. H₂SO₄ was added to the whole aqueous plant crude extract. A reddish-brown color formed which indicated the presence of steroidal aglycone part of the glycoside.
- **Legal's test:** To the hydrolysate 1 ml of sodium nitroprusside solution was added and then it was made alkaline with sodium hydroxide solution and observed for pink to red colour.
- **Borntreger's test:** Hydrolysate was treated with chloroform and the chloroform layer was separated. To this equal quantity of dilute ammonia solution was added. No colour change in ammonical layer was observed^[8].

Experimental Animals

Swiss Albino mice either sex weighing between 18-25g were selected for Anti-asthmatic studies. The animals were acclimatized to standard diet and water with add libitum for 14 days before the start of the experiment. The protocol was approved by (Approval: 21/IAEC/CLPT/2016-17) IAEC, Chalapathi Institute of Pharmaceutical Sciences, Guntur (Reg no: 1048/PO/Re/S/07/CPCSEA) as per CPCSEA guidelines.

Drug and Extract Standardization

The extract was suspended in distilled water containing 2% Tween 80 to produce a concentration of 80mg/ml, Ovalbumin I.P (SRL, India) were used to induce Asthma in mice.

Asthma Induction and Assessment of Lung Inflammation

Mice (18-25g), were sensitized with 50µg ovalbumin (OVA) conjugated to 2% aluminium hydroxide in 100µL saline (i.p.). Control mice were given saline injections. Mice were anaesthetized with 5% isoflurane, intranasally challenged with 50µl of 1.5% OVA or saline for the challenges. Mice were treated intraperitoneally with EELI at dose ranges of 100 mg/kg and 200 mg/kg respectively during the OVA challenge period. Appropriate positive and negative controls were carried out in parallel with the treated groups. OVA is challenged from day 1 to day 23

(three weeks for every 7 days), and on day 24, mice were sacrificed, bronchoalveolar lavage (BAL) was performed.

Broncho-Alveolar Lavage Fluid (BALF) and Serum analysis

Blood samples were collected by retro-orbital puncture using heparin capillary tubes. Blood samples were centrifuged (10 minutes, 4°C, 1000g), and plasma was stored at -70°C until use. The lungs were washed three times with 0.5 ml saline to collect BALF. Total number of inflammatory cells in BALF was counted with a hemocytometer. The levels of IL-4 and IL-13 in BALF and total serum Ig E were determined by using ELISA [7].

OVA - Specific Immunoglobulin E Titer by ELISA

After sacrificing the animals, blood samples were collected from mice retro-orbital puncture. Serum OVA specific immunoglobulin E (IgE) were measured in the units of optical density.

Histopathology Studies

Lung sections from EELI treated mice were fixed in Formalin solution, embedded in paraffin. Cut in 0.5-µm sections, and stained with haematoxylin-eosin. Inflammatory parameters in lung tissue (inflammatory cells) were evaluated. Total histology score was calculated and graded from 0 – 4. Where, 0 = normal lung and 4 = diffuse maximal inflammation.

Statistical analysis

Statistical analyses were made using an ANOVA followed by Dunnett's t- test. Statistical significance was determined at $p < 0.05$ and 0.01 .

Results and Discussion

Phytochemical screening of EELI revealed the presence of steroids, flavonoids, tannins, saponins, alkaloids, phenols, carbohydrates and glycosides as the major classes of phytoconstituents.

Table 1: Phytochemical constituents present in EELI

Phytochemical constituent	EELI
Steroids	+
Flavonoids	+
Tannins	+
Saponins	+
Alkaloids	+
Phenols	+
Carbohydrates	+
Proteins	-
Glycosides	+

Eosinophilic Count

Eosinophilic cell counts in the bronchoalveolar lavage (BAL) of intra nasally treated *Lawsonia inermis*. Administration *Lawsonia inermis* significantly reduced the total cell, eosinophil and also lymphocyte accumulation (** $p < 0.001$). Eosinophilic count was significantly increase in diseased control when compared to the normal control was clearly noticed in table-2. It is evidenced that high count of eosinophils indicated the allergic disorder like asthma, eczema etc. due to inflammation of small and medium sized blood vessels [9]. *Lawsonia inermis* treated groups showed the significant reduction of differential eosinophilic cell counts when compared to the disease control group was observed in table 2. This might be due to the anti-inflammatory and antioxidant property of *Lawsonia inermis* against ovalbumin induced lung inflammation. *Lawsonia inermis* protects lung inflammation evidenced by Nitu Singh in 2015 i.e chloroform extract of *Lawsonia inermis* possesses dose dependent, significant synergistic anti-inflammatory activity against inflammation [10].

Total Leucocytic Count

The levels of Th-2 cytokines IL-4 and IL-13 in the BALF and total serum IgE were increased significantly by airway challenge with OVA when compared with the control group. The administration of *Lawsonia inermis* reduced the concentrations of Th-2 cytokines and total serum IgE. Total leucocytic count was significantly increase in diseased control when compared to the normal control. It might be due the elevation of WBC count in bronchial asthma [11]. *Lawsonia inermis* treated groups showed significant reduction of elevated Total number of leucocytic count/mm when compared to the disease control group (Table-2). This might be due to the protective action of *Lawsonia inermis* against lung inflammation. *Lawsonia inermis* protects lung inflammation evidenced by Snehal S Manekar in 2019 i.e aerial parts of *Lawsonia inermis* Linn methanolic extract Possesses antioxidant, anti-inflammatory, Bronchodilator properties and also useful in antiasthmatic treatment [12].

Table 2: Broncho-Alveolar Lavage Fluid (BALF) and Serum analysis

Group Treatment	Eosinophilic count	IL-4	IL-13	Hb	TLC	BALF-TLC	Epithelial Cells	IgE (ng/ml)
Normal	27.4 ± 1.32	18 ± 0.24	11 ± 1.21	13.2 ± 0.21	13.24 ± 0.8	9.27 ± 0.35	3.13 ± 0.21	0.2162
Control (Ovalbumin)	167 ± 5.4	45 ± 1.31	26 ± 0.74	10.4 ± 0.12	24.3 ± 1.51	38.3 ± 1.52	14.39 ± 0.19	0.8729
Ovalbumin + EELI (100 mg/kg)	106 ± 3.2*	38 ± 0.44*	22 ± 0.58*	9.32 ± 0.25	17.2 ± 1.21*	23.2 ± 0.3*	6.23 ± 0.4*	0.6123
Ovalbumin + EELI (200 mg/kg)	86 ± 1.4**	33 ± 0.89**	18 ± 0.27**	11.9 ± 0.21	16.4 ± 1.13**	19.09 ± 1.2**	4.93 ± 0.15**	0.5452

All values are shown as Mean ± SEM and n=6, ** $p < 0.01$ indicate when compared with Control group, * $p < 0.05$ indicate when compared with Normal group.

Lung Histology

Histological analysis of the lungs from non-sensitized i.e. group-I showed normal lung histology. In contrast, to the BALF study, histological sections of lung tissue from group II mice exhibited airway Inflammation of the airway, infiltration of eosinophils, lymphocytes, sub-mucosal oedema of the lungs, bronchoconstriction seen as mucus lumen plugging and treatment of cells with *Lawsonia inermis* group III and group IV inflammatory cell infiltration and airway lumen plugging, thereby minimizing inflammation, broncho-constriction leading to regular lumen size. Bronchial asthma is characterized by the wide spread narrowing of the bronchial tree due to the contraction of the smooth muscle in response to many stimuli resulting in the release of chemical mediators such as histamine [13].

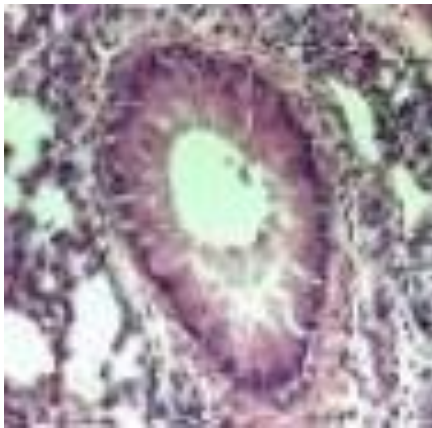


Fig 1: Normal

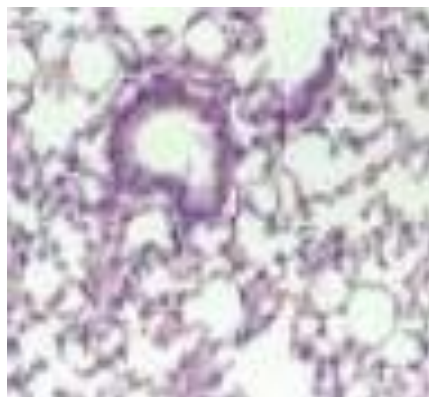


Fig 2: Control (OVA induced)

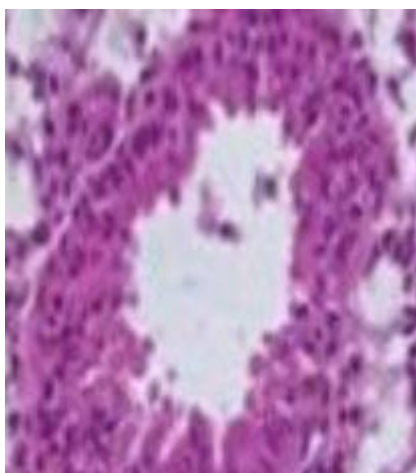


Fig 3: OVA+ EELI (100 mg/kg)

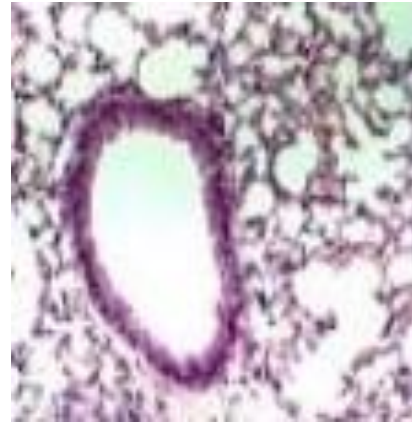


Fig 4: OVA+EELI (200 mg/kg)

The results from the current study suggest that, there was substantial decreasing severity of symptoms of asthma and there also exists a simultaneous improvement in lung function parameters. The present study was carried out to verify that EELI have broncho-dilating activity, a significant number of therapeutic approaches for bronchial asthma have been designed based on the antagonism of specific mediators released from mast cells. For initiating immediate responses after exposure to allergens, mast cell degranulation is critical will play a significant role in airway inflammatory response, airway eosinophilia. Degranulation of mast cells has been taken as the criteria of positive anaphylaxis. The degree of bronchial hyper-responsiveness and airway obstruction is closely linked to the extent of inflammation. Anti-inflammatory drugs suppress the inflammatory response by inhibiting infiltration and activation of inflammatory cells as well as their synthesis, or release and the effects of inflammatory mediators [14]. Alcoholic extract of *Lawsonia inermis* possess potent anti-inflammatory activity. Since, serotonin, histamine and prostaglandins are the common mediators of both bronchial asthma and inflammation, the beneficial effect of EELI could be due to inhibition of their release possibly due to COX inhibition leading to inhibition of prostaglandin synthesis [15]. Mice lung is used for screening of antihistaminic activity. Since it can be sensitized with minor doses as it has well developed immune system. EELI (100 mg/kg, 200mg/kg) significantly inhibited the Ovalbumin induced contraction of mice lung preparation supports the anti-asthmatic activity [16]. While additional studies are needed to explain the mechanistic basis for this finding, due to the larger diffusion region, epithelial damage mediated asthmatic pathophysiology was more serious OVA sensitization. Thus, epithelial cytokines produced by weakened epithelial cells contribute in part to asthma's pathophysiological trends according to the mode of distribution after sensitization of the allergen [17].

Conclusion

The study revealed that alcoholic extract of *Lawsonia inermis* showed significant *anti-asthmatic* activity by reducing the eosinophilic count and total leucocytic count to normal which might be due to minimizing inflammation, broncho-constriction leading to regular lumen size and which was further supported by histopathological studies. Anti-asthmatic activity of *Lawsonia inermis* can be attributed to its broncho dilating and anti-inflammatory property.

Acknowledgement

Authors are thankful to Principal and management of Chalapathi Institute of Pharmaceutical Sciences for providing necessary support for carrying the research work.

Conflict of Interest

Nil

References

1. Lidiane Maria, Boldrini-Leite, Pedro Vicente Michelotto Jr, Sérgio Adriane Bezerra de Moura, Luiz Guilherme Achcar Capriglione, *et al.* Lung Tissue Damage Associated with Allergic Asthma in BALB/c Mice Could Be Controlled with a Single Injection of Mesenchymal Stem Cells from Human Bone Marrow up to 14 d After Transplantation. *Cell Transplantation*,2020;29:1-13.
2. Buddhadev SG, Buddhadev S. Ayurvedic Medicinal Plant *Lawsonia Inermis* Linn.: A Complete Review; An International Journal Of Pharmaceutical Sciences,2016;7(2):240-48.
3. Ji-Hye Seo, Mi-Ae Bang, Gyeyeop Kim, Seung Sik Cho, Dae Hun Park. *Erythronium japonicum* attenuates histopathological lung abnormalities in a mouse model of ovalbumin-induced asthma. *Int. J. Mol. Med*,2016;37:1221-1228.
4. Ritesh Kumar Sh, Anjana G. Identification of Phytoconstituents in *Lawsonia inermis* Linn. Leaves Extract by GC-MS and their Antibacterial Potential; *Pharmacognosy Journal*,2018;10(6):1101-1108.
5. Mounica P. A Pharmacological and Toxicological Review of *Lawsonia Inermis*; *International Journal of Pharmaceutical Sciences and Research*,2018;9(3):902-915.
6. Zumrutdal E, Ozaslan M. A miracle plant for the herbal pharmacy; henna (*Lawsonia inermis*). *Pharmacology*,2012;896:483-9. 21.
7. Sreenu T, Jyothibas T, Bhavani P, Subba Reddy T. Antiasthmatic Activity of Alcoholic Extract of *Clerodendrum serratum* induced by Ovalbumin. *Int. J. Chem. Pharm. Sci*,2012;3(1):83-85.
8. Kokate CK, Gokhale SB, Purohit AP *et al.* A Text book of pharmacognosy 56th edition, Nirmal Prakashan, Page no-Appendix-8, A-22-27.
9. Eosinophils. Definition, abnormal ranges and causes. <https://www.sightdx.com/knowledge-center/eosinophil>, 2021.
10. Nitu Singh, Praveen Kumari *et al.* Synergistic anti-inflammatory Activity of *Lawsonia Inermis* linn. and *Chlorophytum Brovillianum sant.* *International Journal of Pharma Research & Review*,2015;4(2):21-25.
11. Asthma and White blood cell count increased. *E Health Me. com.* <https://www.ehealthme.com/cs/asthma/white-blood-cell-count-increased/>. 2021.
12. Snehal S Manekar, Manoj S Charde. Evaluation of anti-asthmatic activity of *Lawsonia inermis* Linn. Aerial parts. *The Pharma Innovation Journal*,2019;8(5):86-91.
13. Ian C Guest, Stewart Sel. Bronchial lesions of mouse model of asthma are preceded by immune complex vasculitis and induced bronchial associated lymphoid tissue (iBALT). *Laboratory Investigation*,2015;95:886-902.
14. Stumm CL, Halcsik E, Landgraf RG, Camara NOS, Sogayar MC. Lung Remodeling in a Mouse Model of Asthma Involves a Balance between TGF- β 1 and BMP-7. *PLoS ONE*,2014;9(4):e95959(1-9).
15. Rawiwan Ch, Thidarat D, Chanida P, Nijsiri R. Pharmacognostic specifications and lawsone content of *Lawsonia inermis* leave; *Pharmacognosy Research*,2017;9(1):60-64.
16. Sreenu T, Jyothibas T, Venkata Ramana K, Subba Reddy T. Antiasthmatic Activity of Alcoholic Extract of *Physalis angulata* induced by Ovalbumin. *Am. J. Pharm. Tech. Res*,2012;2(6):892-897.
17. Dong Im Kim, Mi-Kyung Song and Kyuhong Lee. Comparison of asthma phenotypes in OVA induced mice challenged via inhaled and intranasal routes. *BMC Pulm. Med*,2019;19:241:1-11.